

# Laparoscopy in Abdominal Trauma

Selman Uranüs<sup>1</sup>, Katrin Dorr<sup>2</sup>

## Abstract

**Background:** The decision in favor of surgery or nonoperative conservative treatment in blunt and penetrating abdominal trauma requires a precise diagnosis that is not always possible with imaging techniques, whereby there is great danger that an injury to the diaphragm or intestines may be overlooked. To avoid such oversights, indications for exploratory laparotomy have traditionally been generous, to the extent that up to 41% of exploratory laparotomies turn out to be nontherapeutic and could be, or could have been, avoided with laparoscopy.

**Materials and Methods:** A diagnostic laparoscopy with therapeutic option should only be attempted in stable patients. Three trocars are usually used and the abdomen is explored systematically, beginning with the right upper quadrant and continuing clockwise. Hollow viscus injuries and injuries to the diaphragm and mesentery can be detected and sutured laparoscopically. Injuries to parenchymal organs are not a primary focus of laparoscopy, but with a laparoscopic approach, they usually no longer bleed in stable patients and can be sealed with tissue adhesive and collagen tamponade to prevent re-bleeding.

**Results:** The routine use of laparoscopy can achieve a sensitivity of 90–100% in abdominal trauma. This can reduce the number of unnecessary laparotomies and the related morbidity.

**Conclusion:** Laparoscopy can be performed safely and effectively in stable patients with abdominal trauma. The most important advantages are reduction of the nontherapeutic laparotomy rate, morbidity, shortening of hospitalization, and cost-effectiveness. In the future, new developments in and the miniaturization of equipment can be expected to increase the use of minimally invasive techniques in abdominal trauma cases.

## Key Words

Laparoscopy · Trauma · Abdominal trauma · Diagnosis of abdominal trauma · Therapeutic laparoscopy

Eur J Trauma Emerg Surg 2010;36:19–24

DOI 10.1007/s00068-010-9219-5

## Introduction

Minimally invasive access has assumed an important position in many areas of surgery, but it was only the developments of the last 20 years that allowed laparoscopy and thoracoscopy to come into use as diagnostic and therapeutic methods in visceral trauma. With surgeons' increasing experience, laparoscopy first became routine in elective surgery, and then proved to be effective even under the difficult circumstances posed by visceral trauma.

In most industrialized countries, trauma is the most common cause of death in the younger population below the age of 50 years. About one-half of these deaths take place within minutes at the site of the accident; these are usually severe head and cardiovascular injuries. Thirty percent of the deaths occur within a few hours of the injury and the remaining 20% after days to weeks due to infections and multi-organ failure. In the second group, in which victims die within a few hours, conservative estimates indicate that some 20–30% of them could be saved with timely diagnosis and proper treatment. Laparoscopy has come to play an increasing role in this concept. It is primarily a diagnostic measure, but, when feasible, can also be applied therapeutically.

Although several diagnostic methods are available for the evaluation of trauma patients, prompt recognition of abdominal injury still poses a significant clinical challenge, particularly in patients who have no obvious indications for emergent surgery. The

<sup>1</sup>Department of Surgery, Medical University Graz, Universitätsklinik für Chirurgie, Graz, Austria,

<sup>2</sup>Department of Radiology, Medical University Graz, Graz, Austria.

management of trauma patients should avoid delay, provide prompt diagnosis and appropriate treatment, and avoid complications.

### Materials and Methods

Information on the nature and course of the accident can suggest the nature of the injuries. The clinical examination is an important part of the diagnostic work-up of trauma patients. Bruises and other marks on the body can point to organ injuries that may be present and should be carefully noted and examined. Laboratory tests provide essential information on the extent of organ injuries and bleeding.

After the clinical examination, there are two radiological examinations that, owing to technological developments in the last two decades, have come to provide high-quality information. These are sonography and computed tomography (CT), both of which can be applied quickly and efficiently to trauma patients, whereby hemodynamic stability is a prerequisite for a CT.

Ultrasonography can be performed in the emergency room with a hand-held scanner, usually by a general or trauma surgeon. The Focused Assessment with Sonography Trauma (FAST) protocol is intended to determine the presence of free fluid in the abdominal cavity and assess its quantity and location [1]. It is noninvasive, nonstressful, and can be repeated as necessary. With portable equipment, ultrasonography can be performed in emergency cases simultaneously with ongoing resuscitation without sedation, and it can also be done at the bedside without moving the patient. Rozycki et al. achieved a sensitivity of 83.3% and a specificity of 99.7% in 1,540 patients with blunt and penetrating injuries [2].

CT scanning is noninvasive and can provide valuable supplemental information on the size, number, and extent of pathological changes. The findings can be determined very precisely and reproducibly. This method competes with ultrasound, which requires interpretation by an experienced operator at the time of scanning. With CT, the quality of scanning does not depend much on the experience of the person administering it. CT has 97% sensitivity, 98% specificity, and 98% accuracy for peritoneal violation [3]. In detecting bowel injury, CT has an overall sensitivity of between 94 and 96% in detecting mesenteric injury [4].

Both sonography and CT show a weakness in diagnosing injuries to the diaphragm: Mihos et al. [5] achieved a correct preoperative diagnosis in only 26%

of 65 patients with a diaphragmatic injury, while in 74%, the diagnosis was made during the operation.

### Why Laparoscopy?

Although the noninvasive methods provide high-quality information, there is still a degree of diagnostic uncertainty with blunt abdominal trauma, especially when the gastrointestinal tract, pancreas, and diaphragm are involved. This uncertainty in the diagnostic process was, and is, an important justification for exploratory laparotomies undertaken to avoid missed injuries. A considerable number of these laparotomies are unnecessary or nontherapeutic and have corresponding morbidity [6].

The literature shows that a variety of laparoscopic techniques produce good results with abdominal trauma. In a review by Villavicencio and Aucar, two prospective studies of screening laparoscopy for blunt trauma reported a sensitivity of 90–100%, specificity of 86–100%, and accuracy of 88–100% [7]. In nine prospective series, screening laparoscopy for penetrating trauma reported a sensitivity of 85–100%, specificity of 73–100%, and accuracy of 80–100%, with two procedure-related complications among 543 patients [7]. Diagnostic laparoscopy for blunt trauma reported a sensitivity of 100%, specificity of 91%, and accuracy of 96%, and for penetrating trauma a sensitivity of 80–100%, specificity of 38–86%, and accuracy of 54–89% [7]. Missed injuries with screening laparoscopy were 0.4% (6 of 1,708 patients) and laparoscopy-related complications were 1.3% (22 of 1,672 patients) [7]. Laparoscopy can prevent laparotomy in 63% of patients with a variety of injuries [7]. The laparoscopic approach avoids a negative laparotomy in 23–54% of patients with stab wounds and blunt abdominal trauma [8]. Laparoscopy is more cost-effective than negative laparotomy [9, 10].

### Indications

The most common indications for laparoscopic diagnosis and treatment may be summarized as follows (Table 1):

- (1) *Free fluid of unknown source* Some trauma patients have as blood diagnosed free fluid in the peritoneal cavity, but the source of bleeding cannot be determined. In these patients, nonoperative treatment is usually a risky option. The source is mostly a mesenteric laceration which will often be

**Table 1.** Indications for a diagnostic and/or therapeutic laparoscopy in abdominal trauma.

**Indications for laparoscopy in trauma**

1. Suspected mesenteric laceration
2. Suspected hollow viscus injury
3. Suspected vascular damage to the intestine
4. Unclear symptoms in the absence of any injury
5. Pancreatic injury
6. Penetrating trauma

missed with CT scanning and detected laparoscopically.

- (2) *Blunt trauma – suspected intestinal injury* When an intestinal injury is suspected with blunt abdominal trauma, the extent of injury and/or of ongoing bleeding is usually unclear. Laparoscopy can provide a secure diagnosis with therapeutic potential (sewing over the laceration or resection) and, so, is a good and safe option.
- (3) *Injury to the mesentery – unclear vascular damage to the intestine* When CT has shown one or more mesenteric lacerations, but it remains unclear whether the perfusion of the involved segment of the intestine is adequate or ischemic necrosis is a threat, laparoscopy can visualize the injury and help assess intestinal vitality, so that appropriate surgical measures can be taken.
- (4) *Unclear abdomen after blunt trauma* The term “unclear abdomen” indicates a discrepancy between the findings of imaging studies and clinical examination. In spite of conservative treatment, the patient’s diffuse and unspecific symptoms do not improve. These symptoms may be due to pre-existing conditions such as adhesions or internal hernia, or to new developments such as volvulus, that have nothing to do with the trauma. Laparoscopy can quickly clarify such situations and may also provide a therapeutic option.
- (5) *Pancreatic injury – no time pressure* This is usually a matter of superficial injury without ductal involvement that does not require any immediate surgical or interventional radiologic treatment. If symptoms develop or become more severe, such injuries can be necrotomized and drained laparoscopically.
- (6) *Penetrating trauma – stable patient* With stab wounds, laparoscopy allows the diagnosis of peritoneal penetration and subsequent exploration for other organ injuries. Depending on the severity, the laparoscopic treatment of organ injuries such

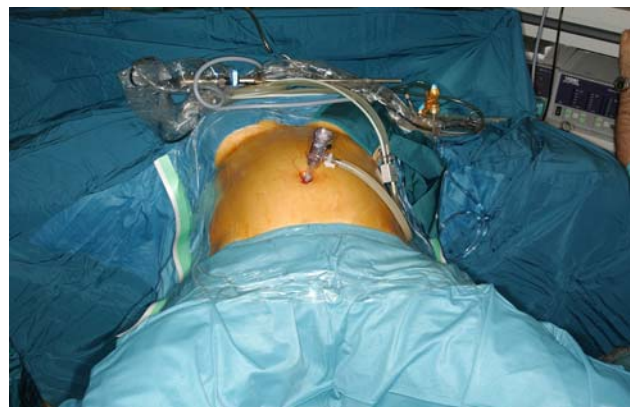as those to the stomach wall or intestine may be possible. There is an increased advantage with diagonal thoracoabdominal stab or gunshot wounds in the flank, as a CT diagnosis may miss an injury to the diaphragm. In these cases, the wound can be explored laparoscopically or thoracoscopically to determine whether laparotomy, thoracotomy, or a minimal access procedure is indicated.

**Technique of Laparoscopy in Trauma**

The positioning and preparation of the patient for trauma laparoscopy is essentially the same as for a trauma laparotomy. Conversion to conventional open approach to the thorax and abdomen should be possible without delay or additional preparation. As for every trauma laparotomy, the inguinal region should be accessible (Figure 1). The first access is achieved with the open technique using a 5- or 10-mm trocar at the navel. Gas for the pneumoperitoneum should be insufflated slowly and carefully. If the blood pressure drops or respiratory pressure suddenly rises, insufflation is stopped or the gas pressure reduced. In this case, laparoscopy can only be done with reduced gas pressure or with the gasless technique.

After a preliminary inspection of the entire abdominal cavity, two further trocars are introduced on the right and left sides at the level of the navel and somewhat lateral to the medioclavicular line. These working trocars have a diameter of 5–10 mm (Figure 2).

The abdomen is explored systematically, beginning with the right upper quadrant and proceeding clockwise. After a first fast survey, the exploration continues



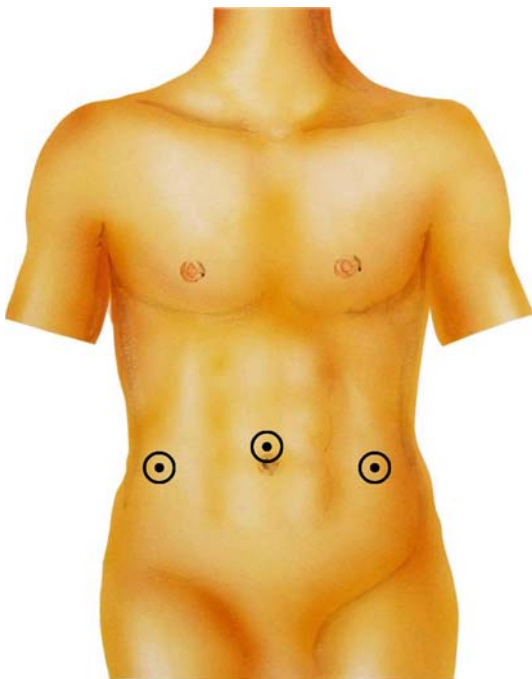**Figure 1.** Patient’s position on the operating table for a trauma laparotomy or laparoscopy.

in the same order for a second time. If there is no injury to the hollow viscus, blood can be vacuumed off into a Cell Saver<sup>®</sup>. It is advantageous during this phase of the operation to have the table in the anti-Trendelenburg position to shift the abdominal organs caudally. In the supine position, the spleen is covered by the greater omentum and is not immediately visible. After the anterior wall of the stomach is inspected, the omentum is shifted caudally and the spleen is lifted from its bed with a blunt instrument. While the liver and spleen are being examined, the diaphragm can also be inspected. Even the most remote parts of the diaphragm can be seen much better laparoscopically than with the open technique.

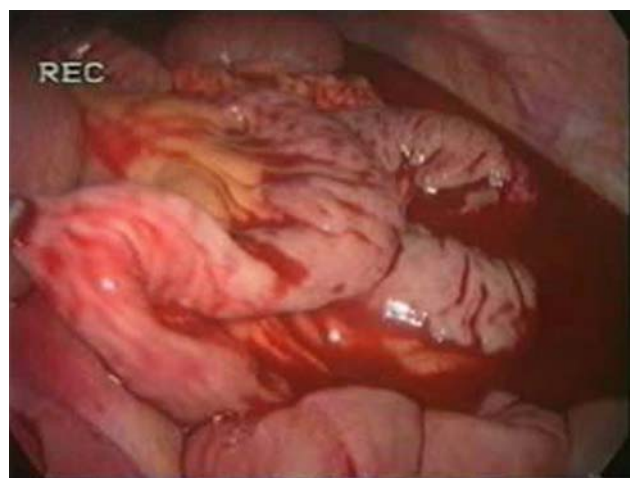
After the upper abdominal organs, the left flank with the left flexure, descending colon, and sigmoid are examined for injuries down to the left lower quadrant. Then, the operating table is brought into the Trendelenburg position for examination of the rectum, Douglas' space, urinary bladder, and, in women, the internal genital organs. The examination is continued in the right lower quadrant with the cecum and right hemicolon. The omentum is shifted cranially so that the small intestine can be examined. Using two atraumatic grasping forceps, the small intestine is followed from the ileocecal region in the oral direction to the duodenal-jejunal flexure (Figure 3). Exploration of the duodenum, posterior gastric wall, and pancreas is only

indicated when injury to these organs is suspected. It is justified when there are hematomas or thrombi adherent on these organs and/or on the basis of a CT image.

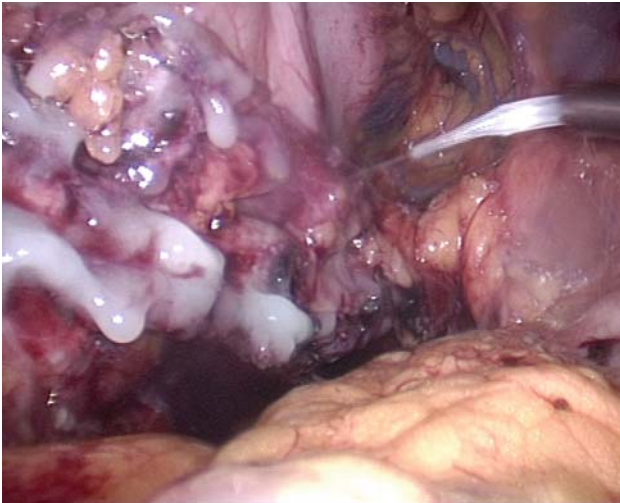Treatment depends on the equipment available in the respective hospital and the surgeon's experience. While simple lacerations of the intestine or mesentery can be sutured with monofile 3/0 thread, extensive deceleration injuries to the intestines can only be treated quickly and safely with the open technique. Minor injuries to the diaphragm can be dealt laparoscopically with sutures or suitable PTFE prosthetic material. Blunt abdominal trauma with active bleeding requires open surgery. In stable patients, sources of bleeding, either small vessels or such that have already ceased to bleed, can be closed with 3/0 monofile sutures or with modern coagulation devices (ultrasonic coagulator or LigaSure<sup>®</sup>). Large wound surfaces and lacerations of solid organs can be quickly and effectively sealed laparoscopically with fibrin adhesive (Figure 4) and tamponaded in combination with collagen fleece (Figure 5). Even with these adhesive and coagulative options, laparoscopy is not indicated for actively bleeding spleen and liver injuries. These injuries should only be treated laparoscopically when a primary laparoscopy has been undertaken for other reasons. In stable patients, liver and spleen injuries that do not show active bleeding upon CT are basically handled conservatively and not with surgery [9]. If laparoscopy is required to rule out intestinal injury, the measures mentioned above can be applied to prevent renewed bleeding.



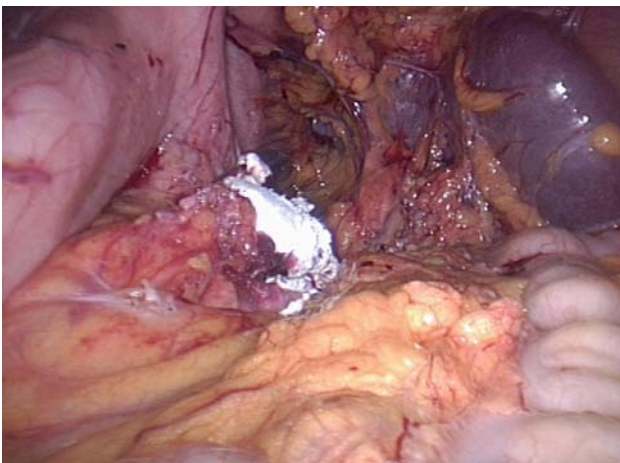
**Figure 2.** Trocar positions for a trauma laparoscopy.



**Figure 3.** Laparoscopic view of a mesenteric laceration in a case of blunt abdominal trauma.



**Figure 4.** Laparoscopic treatment of a pancreas lesion using an autologous fibrin adhesive (Vivostat®).



**Figure 5.** Laparoscopic collagen-fleece (Lyostypt®) tamponade of the pancreas.

Trauma laparoscopy can be complicated in patients with extensive adhesions. In such cases, adhesiolysis should be limited on the basis of CT findings to the suspicious area. Extensive laparoscopic adhesiolysis can take more time than with the open technique and entail higher morbidity.

#### The Risks of Laparoscopy in Trauma

Laparoscopy in blunt abdominal trauma entails three risks, which, in order of their importance, are: (1) missing injuries, mainly involving the intestinal tract, with delayed treatment and considerably increased morbidity as consequences; (2) laparoscopy-specific

complications, such as vascular and intestinal injuries; (3) gas embolism.

Missed injuries as the most common of these three problems probably pose the most serious risk, though the literature data are very unclear on this. While some authors find that laparoscopy is inadequate for detecting intestinal injuries [12, 13], other centers, including ours, do not report any missed injuries [8, 11]. With increasing experience with laparoscopy in acute care surgery, there has been a significant improvement in the results, even with trauma, in the form of fewer negative laparotomies, shorter hospitalization, and lower treatment costs [10, 14, 15].

Although it is theoretically possible, gas embolism has not yet been reported in trauma patients with intraabdominal venous injuries.

#### Discussion

The range of applications for laparoscopy has greatly expanded with technical advances and the constantly increasing experience with it in acute care surgery, including trauma surgery. Trauma centers throughout the world have developed their own algorithms for handling blunt and penetrating abdominal trauma to assure the fast and effective diagnosis of visceral injuries. The usual diagnostic procedures of diagnostic peritoneal lavage (DPL), sonography, and CT all have their strengths and weaknesses, and none of them are 100% reliable. For this reason, exploratory laparotomy is often performed in the case of stab wounds, but the associated morbidity can reach up to 40% [6]. The main benefits of laparoscopy are that it can reduce the rate of nontherapeutic and negative laparotomies, identify diaphragmatic injuries accurately, and, in some cases, provide a therapeutic option. It should be emphasized that the use of laparoscopy in patients with trauma is reserved for hemodynamically stable patients and that laparoscopy can have limitations in dorsal stab injuries to the hollow viscus. The opinion in the early 1990s, supported by published data, that there was a higher incidence of complications with laparoscopy is now outdated, due to increasing experience and technical improvements [7]. Success can very much depend on the correct choice of trocar positions. For therapeutic maneuvers, the triangulation of the area of injury is immensely important for intracorporeal sewing and suturing. Organs can be shifted by changing the position of the operating table so that the surgical field can be better visualized without additional trocars and retractors.

Potential risks when trauma patients undergo laparoscopy include air embolism, the elevation of intracerebral pressure with head injuries, and tension pneumothorax when the diaphragm is injured. Small numbers of such complications were reported in the 1990s, and they now seem to be preventable if suitable measures are taken [16, 17]. These problems are not reflected in the newer literature.

Minimally invasive surgery has become established as a useful tool in the management of trauma. Laparoscopy can detect and repair injuries to the hollow viscus and diaphragm and exclude the risks of non-therapeutic laparotomy. Further advantages are reduced morbidity, shortened hospital stay, and lower cost. The future holds exciting advances for this field of surgery through innovative developments

#### Conflict of interest statement

The authors declare that there is no actual or potential conflict of interest in relation to this article.

#### References

- Ballard RB, Rozycki GS, Newman PG, Cubillos JE, Salomone JP, Ingram WL, Feliciano DV. An algorithm to reduce the incidence of false-negative FAST examinations in patients at high risk for occult injury. *J Am Coll Surg* 1999;189:145–51.
- Rozycki GS, Ballard RB, Feliciano DV, Schmidt JA, Pennington SD. Surgeon-performed ultrasound for the assessment of truncal injuries: lessons learned from 1,540 patients. *Ann Surg* 1998;228:557–67.
- Shanmuganathan K, Mirvis SE, Chiu WC, Killeen KL, Hogan GJF, Scalea TM. Penetrating torso trauma: triple-contrast helical CT in peritoneal violation and organ injury – a prospective study in 200 patients. *Radiology* 2004;231:775–84.
- Killeen KL, Shanmuganathan K, Poletti PA, Cooper C, Mirvis SE. Helical computed tomography of bowel and mesenteric injuries. *J Trauma* 2001;51:26–36.
- Mihos P, Potaris K, Gakidis J, Paraskevopoulos J, Varvatsoulis P, Gougoutas B, Papadakis G, Lapidakis E. Traumatic rupture of the diaphragm: experience with 65 patients. *Injury* 2003;34:169–72.
- Leppäniemi A, Salo J, Haapiainen R. Complications of negative laparotomy for truncal stab wounds. *J Trauma* 1995;38:54–8.
- Villavicencio RT, Aucar JA. Analysis of laparoscopy in trauma. *J Am Coll Surg* 1999;189:11–20.
- Chol YB, Lim KS. Therapeutic laparoscopy for abdominal trauma. *Surg Endosc* 2003;17:421–7.
- Smith RS, Fry WR, Morabito DJ, Koehler RH, Organ CH Jr. Therapeutic laparoscopy in trauma. *Am J Surg* 1995;170:632–6.
- Taner AS, Topgul K, Kucukel F, Demir A, Sari S. Diagnostic laparoscopy decreases the rate of unnecessary laparotomies and reduces hospital costs in trauma patients. *J Laparoendosc Adv Surg Tech A* 2001;11:207–11.
- Uranüs S, Pfeifer J. Nonoperative treatment of blunt splenic injury. *World J Surg* 2001;5:1405–7.
- Ivatury RR, Simon RJ, Stahl WM. A critical evaluation of laparoscopy in penetrating abdominal trauma. *J Trauma* 1993;34:822–8.
- Livingston DH, Tortella BJ, Blackwood J, Machiedo GW, Rush BF Jr. The role of laparoscopy in abdominal trauma. *J Trauma* 1992;33:471–5.
- Gorecki PJ, Cottam D, Angus LD, Shaftan GW. Diagnostic and therapeutic laparoscopy for trauma: a technique of safe and systematic exploration. *Surg Laparosc Endosc Percutan Tech* 2002;12:195–8.
- Chelly MR, Major K, Spivak J, Hui T, Hiatt JR, Margulies DR. The value of laparoscopy in management of abdominal trauma. *Am Surg* 2003;69:957–60.
- Leppäniemi A, Haapiainen R. Diagnostic laparoscopy in abdominal stab wounds: a prospective, randomized study. *J Trauma* 2003;55:636–45.
- Fabian TC, Croce MA, Stewart RM, Pritchard FE, Minard G, Kudsk KA. A prospective analysis of diagnostic laparoscopy in trauma. *Ann Surg* 1993;217:557–65.

#### Address for Correspondence

Selman Uranüs MD, FACS  
 Department of Surgery  
 Medical University Graz  
 Universitätsklinik für Chirurgie  
 Auenbruggerplatz 29  
 8036 Graz  
 Austria  
 Phone (+43/316) 385-81196, Fax -6845  
 e-mail: selman.uranues@medunigraz.at